

SPECIAL ARTICLE

The Terminology and Diagnostic Criteria Committee of The Japan Society of Ultrasonics in Medicine*

Criteria for the diagnosis of developmental dysplasia of the hip joint

A frontal image of the hip joint of an infant, defined as standard ultrasonographic image by the Japan Society of Ultrasonics in Medicine (Fig. 1), is used for the classification. The angles α and β formed by the three reference lines shown in Fig. 1 are measured. Developmental dysplasia is classified on the basis of these two angles and the age of the infant, as shown in Table 1 (reproduced with modification with permission of Graf).

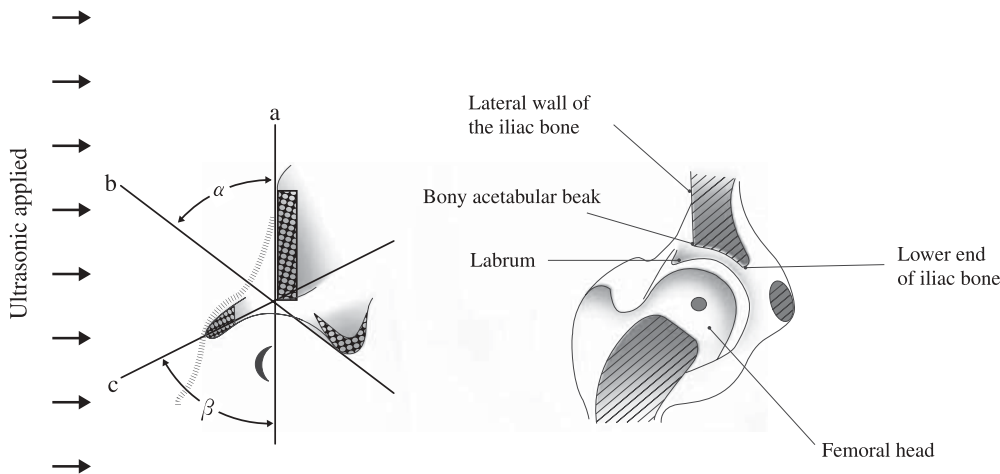


Fig. 1. Frontal image of the hip joint. **a** Baseline: a line passing the point of contact between the perichondrium and the lateral wall of the iliac bone that is parallel to the lateral wall of the iliac bone. **b** Bony roof line: a line connecting the bony acetabular beak and the lower end of the iliac bone. **c** Cartilage roof line: a line connecting the bony acetabular beak and the center of the labrum

*Chairperson: Sachiko Tanaka

*Collaborators

Members of Subcommittee of The Developmental Dysplasia of the Hip Joint of The Terminology and Diagnostic Criteria Committee of The Japan Society of Ultrasonics in Medicine
Chairperson: Yoshihiro Semoto
Hirofumi Ohgiya · Hiromi Matsuzaki

Table 1. Classification of developmental dysplasia of the hip joint

Type		Shape of bony acetabular rim	Shape of acetabular cartilage	α angle	β angle ^b
I	Normal hip	Angular or slightly roundish	Narrow; the femoral head is covered well	$\alpha \geq 60$	
II	IIa. Delayed ossification of bony acetabulum (less than 3 months after birth)	Roundish	Wider; the femoral head is covered	$50 \leq \alpha < 60$	
	IIb. Dysplasia of bony acetabulum (after 3 months)		Wider; the femoral head is covered almost completely		
	IIc. Danger of dislocation	Slightly flat			$70 \leq \beta \leq 77$
D	Afferent nature lost in the femoral head (acetabular dysplasia is less severe than types III and IV)		Femoral head is not covered	$43 \leq \alpha < 50$	$\beta > 77$
III	IIIa. No echo in acetabular cartilage	Flattened	Acetabular cartilage located superomedial to the femoral head	$\alpha < 43^a$	
	IIIb. Echo seen in acetabular cartilage				
IV	Severe dislocation		Acetabular cartilage located inferomedial to the femoral head		

^aThe angle α does not need to be measured if the acetabular cartilage is evidently located medially

^bThe angle β is used only for discrimination of Type IIc from Type D

References

1. Graf R. Guide to sonography of the infant hip. Stuttgart: Thieme Medical 1987. p. 42–53.
2. Semoto Y, Onomura T. Ultrasonography of the infant hip. Orthopedic Surgery 1988;13:327–32 (in Japanese).
3. Honma M, Hatakeyama S. The comparison between sonography and roentgenography in CDH screening. J JaSOU 1992;4:64–7 (in Japanese).
4. Yamazaki Y, Kuroki Y, Saito S, et al. A comparison between the arthrogram and the sonogram in congenital dislocation of the hip. J JaSOU 1993;5:75–8 (in Japanese).